REVIEW PAPER ON GLAUCOMA DISEASE

CHINMAYI HULMANI ,Dept. Of CS&E,UBDT College of Engineering DAVANGER-004,**chinmayidh@gmail.com**
DARSHAN M N, Dept. Of CS&E,UBDT College of Engineering DAVANGERE-004, **mndarshan01@gmail.com**
DARSHAN T S, Dept. Of CS&E,UBDT College of Engineering DAVANGERE-004,**darshants08dvg@gmail.com**
DEVARAJ, Dept. Of CS&E,UBDT College of Engineering DAVANGERE-004,**devrajar112233@gmail.com**
Dr. MOHAMMAD RAFI, Prof in Dept. Of CS&E,UBDT College of Engineering DVG-004,**mdrafi2km@yahoo.com**

ABSTRACT:

Glaucoma is a common eye disease that can cause irreversible blindness if left undiagnosed and untreated. Glaucoma is a leading cause of blindness in the United States and other industrialized countries. In most cases, the symptoms of early-stage glaucoma are minimal or nonexistent. There are several different types of glaucoma, and they have been classically divided into the categories of primary or secondary open-angle or angle-closure glaucoma. Secondary forms of glaucoma are caused by various ocular or systemic diseases.

Every available treatment to prevent progressive glaucomatous optic neuropathy has potential adverse effects and involves a certain amount of risk and financial expense. Conventional firstline treatment of glaucoma usually begins with the use of a topical selective or nonselective βblocker or a topical prostaglandin analog. Second-line drugs of choice include α-agonists and topical carbonic anhydrase inhibitors.

Parasympathomimetic agents, most commonly pilocarpine, are considered third-line treatment options. For patients who do not respond to antiglaucoma medications, laser trabeculoplasty and incisional surgery are further methods that can be used to lower intraocular pressure. The results of clinical trials have reaffirmed the utility of antiglaucoma medications in slowing the progression of the disease.

Objective of the paper is to highlight the various work on the glaucoma.

Keywords: Carbonic anhydrase inhibitors, Costs, Glaucoma, Lasers, Miotics, Optic nerve diseases, Parasympathomimetic agents, Pilocarpine, Prostaglandins, Surgery, Sympatholytic agents, Toxicity.

INTRODUCTION:

Glaucoma is the main reason of visual disability across the world [1] and it has no cure. At an early stage, if it is not detected then it can definitely be the cause of permanent blindness. There are cures to prevent the vision loss if it is recognized at an early stage. Since, it is a salient chronic eye disease that develops permanent blindness. In recent years, the glaucoma is rapidly increasing even in urban regions. By the year of 2020 [2], it was estimated that it might be affected 79 million people in the world. Thus, it is important to do eye screening for detecting of glaucoma. The eye screening process is expected to tedious and time consuming task due to checkup of every individual patients, which is generally large.



Fig: Normal vision vs. patient having glaucoma

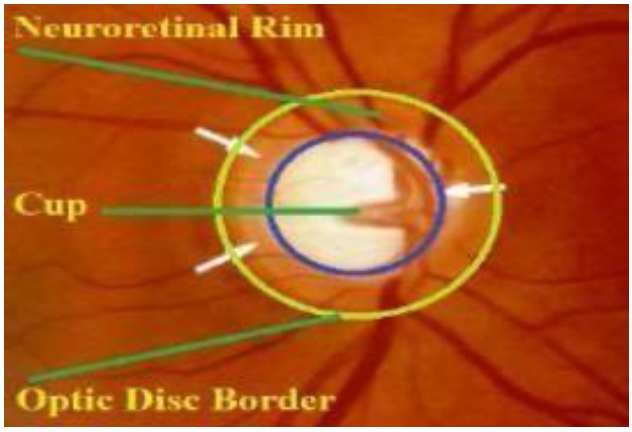

Fig: Major Structures of the ONH visible in colour fundus image

Symptoms of glaucoma:

The symptoms of glaucoma can vary depending on the type of glaucoma and the severity of the condition. In many cases, glaucoma has no noticeable symptoms in the early stages and can go undiagnosed until significant vision loss has occurred.

The most common symptoms of glaucoma include:

- Gradual loss of peripheral
- vision Halos around lights.
- Blurred vision
- Eye pain
- Redness of the eye

Types of glaucoma: There are several types of glaucoma, including:

➢ **Open-angle glaucoma**

- No symptoms in early stages
- Gradually, patchy blind spots in your side vision. Side vision also is known as peripheral vision
- In later stages, difficulty seeing things in your central vision

➢ **Acute angle-closure glaucoma**

- Severe headache
- Severe eye pain
- Nausea or vomiting
- Blurred vision
- Halos or colored rings around lights
- Eye redness

➢ **Normal-tension glaucoma**

- No symptoms in early stages
- Gradually, blurred vision
- In later stages, loss of side vision

➢ **Glaucoma in children**

- A dull or cloudy eye (infants)
- Increased blinking (infants)
- Tears without crying (infants)
- Blurred vision
- Near-sightedness that gets worse
- Headache

➢ **Pigmentary glaucoma**

- Halos around lights
- Blurred vision with exercise

Risk factors for glaucoma:

There are several risk factors for glaucoma, including

➢ **Age:**
The risk of glaucoma increases with age, especially after the age of 60.

- **Family history:**
  Individuals with a family history of glaucoma are at an Increased risk of developing the condition.

- **Ethnicity:**
  African Americans, Hispanics, and individuals of Asian descent are at a higher risk of glaucoma compared to whites.

- **Medical conditions:**
  Individuals with diabetes, high blood pressure, or cardiovascular disease are at an increased risk of glaucoma.

- **Previous eye surgery or injury:**
  Individuals who have had eye surgery or eye injuries are at an increased risk of developing glaucoma.

LITERATURE SURVEY:

In [3], **X. Chen, Y. Xu, D. Wing Kee Wong, T. Yin Wong, J. Liu**, developed a convolutional neural network (CNN) architecture to automate the detection process of glaucoma. The CNN model is having multilayer architecture which belongs to the class of deep-learning algorithms. In that study, the authors make a clear differentiation between glaucoma and non-glaucoma patterns through hierarchical representation of features by CNN model. They used six multilayers of CNN model and divided into four convolutional layers along with two fully connected layers. They performed experiments on ORIGA and SCES datasets and achieved 0.8321 and 0.887 of AUC values, respectively for detection of glaucoma eye disease.

D. W. Kee Wong, T. Y. Wong and J. Liu ,reported that this developed system obtained accomplished better results compared to state of-the-art systems. The smallest version of this paper [4] was also represented in conference.

Another version of deep-learning (DL) algorithm was developed in [5] to detect glaucoma eye diseased through the extraction of different features, such as 52 total deviations, mean deviation, and pattern standard deviation values. The authors utilized DL classifier such as a deep feed-forward neural network (FNN). However, the authors combined this DL classifier with other old machine learning classifiers such as random forests (RF), gradient boosting, support vector machine, and neural network (NN). Therefore**, R. Asaoka, H. Murata, A. Iwase, M. Araie**, presented deep ensemble solution for detecting of glaucoma disease. The authors reported that the 92.5% of AUC value was obtained through a deep FNN classifier.

There was another different approach presented in [6]. **H.S. Alghamdi, H.L. Tang, S.A. Waheeb, T. Peto,**utilized the structure of optic disc (OD) to analyse the glaucoma and other eye diseases such as retinal vein occlusion. The authors claimed that the OD is an essential to local the macula and main vascular arcade from retinal fundus images. In the past studies, the authors used OD properties and spatial relationship between OD and the main vascular arcade to diagnostic the eye disease. However, in that paper, the authors used

the structure of OD abnormalities and deep-learning algorithm to determine the glaucoma eye disease.

In [7], a novel algorithm was developed to detect glaucoma using support vector machine (SVM) instead of using advanced deep-learning algorithm along with hybrid feature set**. A. A. Salam, T. Khalil, M.U. Akram, A. Jameel and I. Basit,** also detected color and texture features from retinal fundus images and some other properties of CDR of OD/CUP ratio to determine the severity-level of glaucoma eye disease. This developed approach was evaluated on 100 patients and they obtained the average sensitivity and specificity of are 100 and 87 %, respectively.

X. Chen, Y. Xu, S. Yan, D. Wong, T. Wong, and J. Liu, developed an automatic solution for the detection of glaucoma by using features [8] learning through deep-learning algorithm on retinal fundus images. The authors utilized CNN model to learn the features with linear and nonlinear activation function. They used glaucoma and nonglaucoma patterns to differentiate for training of CNN model. They performed experiments on the ORIGA and SCES datasets and reported 0.838 and 0.898 of AUC values, respectively.

In [9], **M. Claro, L. Santos, W. Silva Fl´avio Ara´ujo, N. Moura,** performed image processing techniques to automatic detection of glaucoma eye disease through ensemble machine learning classifiers. In that paper, the authors presented a system to segment optic disc, extract of texture feature in different color models and classified them by c. **Daugman** () worked on iris recognition technology. Almost all industrial iris recognition systems utilize trademarked algorithms (Daugman) to create the iris code employing 2D Gabor filters. By comparison, wavelet transform and Fourier descriptor are broadly used in pattern recognition (Chen and Bui). The wavelet transform (Mallat) is utilized to analyze the local frequency. Iris segmentation has an important part in the entire system accuracy since it isolates the appropriate portion of iris from the input eye image. The research group recommended several iris segmentation methods. It offers thresholding and histogram based approaches (Khan et al,Ibrahim et al), edge and gradients descriptors (Chen), active contour models (Ross and Shah).

F. Abdullah, R. Imtiaz, H. A. Madni et al., said the effects of exposure to noise and other occurrences on medical images are wellknown. The main aim of pre-processing an image is to enhance quality, reduce noise, resize the image for the required size, and so on. Prior to segmentation, one should first conduct a set of procedures aimed at addressing problems of noise, poor lighting, and retinal structures that affect the processing of the image. Because nonuniform illumination has a propensity to enhance contrast, nonuniform illumination may be corrected by using adaptive histogram equalization.[11]

Literature Summary:

From the above mentioned survey papers, It has been observed that glaucoma disease is sensitive and it is difficult to find. Many people are proposed a different theory to find it. Many of the models are not up to the mark of accuracy. Using multiple machine learning model and large dataset can improve the accuracy of the proposing model.

COMPARATIVE RESULTS:

Ref no	Paper	Algorithm	Accuracy
3.	Challenges In Early Glaucoma Detection	Convolutional neural network (CNN)	88.7%
5.	Detecting Pre perimetric Glaucoma with Standard Automated Perimetry Using a Deep Learning Classifier	Random forests (RF), Neural network (NN).	92.5%
6.	Automatic Optic Disc Abnormality Detection in Fundus Images: A Deep Learning Approach	Deep-learning algorithm	70%
7.	Automated detection of glaucoma using structural and non structural features	Support Vector Machine (SVM)	87%
8.	Automatic Feature Learning for Glaucoma Detection Based on Deep Learning	Convolutional neural network (CNN)	89.8%
9.	Automatic Glaucoma Detection Based on Optic Disc Segmentation and Texture Feature Extraction	Multilayer Perceptron (MLP) model	80%

Table : Comparison of different techniques for detection of glaucoma



Diagnosis of glaucoma:

Glaucoma is typically diagnosed during a comprehensive eye exam. During the exam, the eye care professional will measure the intraocular pressure of the eye and evaluate the optic nerve for signs of damage. They may also perform a visual field test to assess the extent of vision loss. In some cases, additional tests may be necessary to confirm the diagnosis, such as imaging tests or a test to measure the thickness of the cornea.

Diagnosis of glaucoma involves several tests to assess the health of the optic nerve and the extent of vision loss. The most common test for glaucoma is measurement of IOP, which can be done using a tonometer. Other tests may include:

- **Optic nerve examination:**

  The doctor will use a special microscope called an ophthalmoscope to look at the optic nerve and assess its appearance.

- **Visual field testing:**

  This test measures the extent of the visual field, or the area of the visual environment that can be seen at one time. It is used to detect areas of vision loss caused by glaucoma.

- **Imaging tests:**

  Optical coherence tomography (OCT) and scanning laser ophthalmoscopy (SLO) are non-invasive imaging tests that can be used to assess the health of the optic nerve and retina.

CONCLUSION:

Glaucoma is a common eye disease that is usually associated with an elevated intraocular pressure. Treatment options for patients with glaucoma include medications, laser therapy, and incisional surgery. The risks and benefits of each type of treatment must be carefully considered to maximize the treatment's benefits while minimizing adverse effects.

It has been observed that glaucoma disease is sensitive and it is difficult to find. There are no noticeable symptoms of glaucoma until it becomes chronic and so far there is no cure of this disease in last stages. OCT images can be effectively used for glaucoma prediction because of its ability to extract detailed and depth internal structure of eye, which can be used for detecting early symptoms of glaucoma. Many people are proposed a different theory to find it. Many of the models are not up to the mark of accuracy.

REFERENCES:

[1] E. Dervisevic, S. Pavljasevic, A. Dervisevic, S.S Kasumovic, "Challenges In Early Glaucoma Detection," Med Arch., vol. 70, pp. 203–207, June 2016.

[2] R. Bock, J. Meier, L. G. Nyl, G. Michelson, "Glaucoma risk index: automated glaucoma detection from color fundus images," Medical Image Analysis, vol. 14, pp. 471–481, 2010.

[3] X. Chen, Y. Xu, D. Wing Kee Wong, T. Yin Wong, J. Liu, "Glaucoma detection based on deep convolutional neural network," IEEE Eng Med Biol Soc, pp. 715–718, Annual Conf., August 2015.

[4] X. Chen, Y. Xu, D. W. Kee Wong, T. Y. Wong and J. Liu, "Glaucoma detection based on deep convolutional neural network," International Conference of the IEEE Engineering in Medicine and Biology Society (EMBC), Milan, pp. 715–718, 37th Annual Conference, 2015.

[5] R. Asaoka, H. Murata, A. Iwase, M. Araie, "Detecting Preperimetric Glaucoma with Standard Automated Perimetry Using a Deep Learning Classifier," Ophthalmology, vol. 123, pp. 1974–1980, September 2016.

[6] H.S. Alghamdi, H.L. Tang, S.A. Waheeb, T. Peto, "Automatic Optic Disc Abnormality Detection in Fundus Images: A Deep Learning Approach," OMIA3 (MICCAI 2016), pp. 10– 17, Athens, October 2016.

[7] A. A. Salam, T. Khalil, M.U. Akram, A. Jameel and I. Basit, "Automated detection of glaucoma using structural and non structural features," Springerplus, vol. 5, pp. 1–22, 2016.

[8] X. Chen, Y. Xu, S. Yan, D. Wong, T. Wong, and J. Liu, "Automatic Feature Learning for Glaucoma Detection Based on Deep Learning," MICCAI (3), vol. 9351 of Lecture Notes in Computer Science, pp. 669– 677, 2015.

[9] M. Claro, L. Santos, W. Silva Fl´avio Ara´ujo, N. Moura, “Automatic Glaucoma Detection Based on Optic Disc Segmentation and Texture Feature Extraction,” Clei Eletronic Journal, vol. 19, pp. 1–10, August 2016.

[10]Daugman, J. (1998). Recognizing people by their iris patterns. Information Security Technical Report, 3(1), 33-39. Daugman, J. (2004). How iris recognition works. Circuits and Systems for Video Technology, IEEE Transactions on, 14(1), 21-30. Daugman, J. G. (1988). Complete discrete 2-D Gabor transforms by neural networks for image analysis and compression. Acoustics, Speech and Signal Processing, IEEE Transactions on, 36(7), 11691179. Daugman, J. G. (1993). High confidence visual recognition of persons by a test of statistical independence. Pattern Analysis and Machine Intelligence, IEEE Transactions on, 15(11), 1148-1161. Daugman, J. G. (1994). U.S. Patent No. 5,291,560. Washington, DC: U.S. Patent and Trademark Office.

[11] F. Abdullah, R. Imtiaz, H. A. Madni et al., “A review on glaucoma disease detection using computerized techniques,” IEEE Access, vol. 9, pp. 37311–37333, 2021